



Up-to-date Questions and Answers from authentic resources to improve knowledge and pass the exam at very first attempt.
----- Guaranteed.



AACN-CMC Dumps
AACN-CMC Braindumps
AACN-CMC Real Questions
AACN-CMC Practice Test
AACN-CMC Actual Questions



killexams.com

Nursing

AACN-CMC

AACN Cardiac Medicine (Adult)

ORDER FULL VERSION

<https://killexams.com/pass4sure/exam-detail/AACN-CMC>



Question: 1

A patient presents with acute onset dyspnea, tachycardia, and hypotension. Physical examination reveals distended neck veins and muffled heart sounds. These findings are consistent with:

- A. Cardiac tamponade.
- B. Acute pulmonary edema.
- C. Acute coronary syndrome.
- D. Hypertensive urgency.

Answer: A

Explanation: The patient's presentation with acute onset dyspnea, tachycardia, hypotension, distended neck veins, and muffled heart sounds is indicative of cardiac tamponade. Cardiac tamponade occurs when fluid or blood accumulates in the pericardial sac, exerting pressure on the heart and impeding its ability to fill and pump effectively. This leads to hemodynamic compromise, reflected by the patient's symptoms and physical examination findings. Acute pulmonary edema (option B) typically presents with severe respiratory distress, pink frothy sputum, and crackles on auscultation. Acute coronary syndrome (option C) may present with chest pain, ECG changes, and cardiac enzyme elevation. Hypertensive urgency (option D) is characterized by severely elevated blood pressure without evidence of acute end-organ damage.

Question: 2

A patient presents with muffled heart sounds, hypotension, and jugular venous distension. The patient's blood pressure is 80/50 mm Hg. What is the diagnosis?

- A. Myocarditis

- B. Acute pericarditis
- C. Cardiac tamponade
- D. Aortic dissection

Answer: C

Explanation: The clinical presentation of muffled heart sounds, hypotension, jugular venous distension, and low blood pressure is highly suggestive of cardiac tamponade. Cardiac tamponade occurs when fluid accumulates in the pericardial space, compressing the heart and impeding its ability to fill properly. This leads to decreased cardiac output and systemic hypotension. Prompt recognition and intervention, such as pericardiocentesis, are necessary to relieve the tamponade and restore cardiac function.

Question: 3

A patient presents with fatigue, dyspnea on exertion, and peripheral edema. Physical examination reveals an S3 gallop and bilateral crackles on lung auscultation. The diagnosis is:

- A. Dilated cardiomyopathy
- B. Heart failure with preserved ejection fraction (HFpEF)
- C. Heart failure with reduced ejection fraction (HFrEF)
- D. Hypertrophic cardiomyopathy

Answer: C

Explanation: The clinical presentation of fatigue, dyspnea on exertion, peripheral edema, S3 gallop, and crackles on lung auscultation is consistent with heart failure with reduced ejection fraction (HFrEF). HFrEF is characterized by impaired systolic function, leading to decreased cardiac output

and the accumulation of fluid in the lungs and peripheral tissues. It is often associated with dilated cardiomyopathy, a condition characterized by ventricular dilation and impaired contractility.

Question: 4

A patient presents with sudden loss of consciousness and spontaneous recovery. There is no prodrome or associated symptoms. The **MOST LIKELY** cause of syncope is:

- A. Vasovagal syncope
- B. Cardiac dysrhythmia
- C. Orthostatic hypotension
- D. Seizure disorder

Answer: B

Explanation: The sudden loss of consciousness without prodrome or associated symptoms suggests cardiac dysrhythmia as the most likely cause of syncope. Cardiac dysrhythmias, such as ventricular tachycardia or complete heart block, can lead to a transient loss of blood flow to the brain, resulting in syncope. Further evaluation with an electrocardiogram (ECG) and cardiac monitoring is warranted to identify the specific dysrhythmia and guide appropriate management.

Question: 5

A patient is diagnosed with dilated cardiomyopathy. Which of the following interventions is a key component of the management plan for this patient?

- A. Implantable cardioverter-defibrillator (ICD) placement.
- B. Initiation of beta-blocker therapy.

- C. Administration of anticoagulant therapy.
- D. Coronary artery bypass graft (CABG) surgery.

Answer: B

Explanation: In the management of dilated cardiomyopathy, the initiation of beta-blocker therapy is a key intervention. Beta-blockers have been shown to improve cardiac function, reduce symptoms, and decrease the risk of disease progression in patients with dilated cardiomyopathy. Implantable cardioverter-defibrillator (ICD) placement (option A) may be considered in patients at high risk of sudden cardiac death. Anticoagulant therapy (option B) is typically indicated in patients with specific risk factors for thromboembolism, such as atrial fibrillation. Coronary artery bypass graft (CABG) surgery (option D) is not a primary treatment modality for dilated cardiomyopathy unless there is significant coexisting coronary artery disease.

Question: 6

A patient presents with sudden-onset dyspnea, frothy pink sputum, and crackles on lung auscultation. The diagnosis is:

- A. Pulmonary edema
- B. Pneumonia
- C. Acute respiratory distress syndrome (ARDS)
- D. Pulmonary embolism

Answer: A

Explanation: The clinical presentation of sudden-onset dyspnea, frothy pink sputum, and crackles on lung auscultation is highly suggestive of pulmonary edema. Pulmonary edema occurs when there is an abnormal accumulation of

fluid in the lungs, leading to impaired gas exchange and respiratory distress. It is commonly caused by heart failure or fluid overload, and prompt management is necessary to improve oxygenation and relieve symptoms.

Question: 7

A patient presents with severe chest pain, diaphoresis, and dyspnea. The ECG shows ST-segment elevation in the anterior leads. Troponin levels are elevated. Which of the following is the MOST LIKELY diagnosis?

- A. Unstable angina
- B. NSTEMI
- C. STEMI
- D. Stable angina

Answer: C

Explanation: The presentation of severe chest pain, diaphoresis, dyspnea, and ECG findings of ST-segment elevation in the anterior leads, along with elevated troponin levels, is highly suggestive of ST-elevation myocardial infarction (STEMI). STEMI is characterized by complete occlusion of a coronary artery, leading to myocardial ischemia and necrosis. Prompt intervention, such as percutaneous coronary intervention (PCI) or thrombolytic therapy, is crucial to restore blood flow and salvage the myocardium.

Question: 8

A patient presents with fever, malaise, pleuritic chest pain, and a friction rub on auscultation. The diagnosis is:

- A. Pericardial effusion
- B. Myocarditis

- C. Infective endocarditis
- D. Acute pericarditis

Answer: D

Explanation: The clinical presentation of fever, malaise, pleuritic chest pain, and a friction rub on auscultation is consistent with acute pericarditis. Acute pericarditis is characterized by inflammation of the pericardium, the outer lining of the heart. It often presents with chest pain that is worsened by deep breathing or lying flat, along with other systemic symptoms. The presence of a friction rub on auscultation is a classic finding in acute pericarditis.

Question: 9

A patient presents with episodes of rapid heart rate, palpitations, and lightheadedness. An electrocardiogram (ECG) reveals a regular supraventricular tachycardia (SVT) with narrow QRS complexes. Which of the following interventions is the initial treatment of choice for this patient?

- A. Initiation of beta-blocker therapy.
- B. Administration of adenosine.
- C. Electrical cardioversion.
- D. Vagal maneuvers.

Answer: D

Explanation: In the initial treatment of supraventricular tachycardia (SVT) with narrow QRS complexes, vagal maneuvers are considered the first-line intervention. Vagal maneuvers, such as carotid sinus massage or Valsalva maneuver, aim to stimulate the vagus nerve and slow down the heart rate. They are non-invasive and can often terminate or reduce the frequency of SVT episodes. Administration of adenosine (option B) is the second-line intervention if vagal maneuvers are ineffective. Electrical cardioversion (option C) is

reserved for unstable patients or those with hemodynamic compromise. Initiation of beta-blocker therapy (option D) may be considered for long-term management and prevention of SVT recurrence but is not the initial treatment of choice for acute episodes.

Question: 10

A patient presents with elevated cholesterol levels (LDL > 190 mg/dL) and a family history of premature cardiovascular disease.

- A. Hyperlipidemia
- B. Metabolic syndrome
- C. Atherosclerosis
- D. Familial hypercholesterolemia

Answer: D

Explanation: The combination of elevated cholesterol levels (LDL > 190 mg/dL), a family history of premature cardiovascular disease, and the presence of a genetic predisposition suggests the diagnosis of familial hypercholesterolemia. Familial hypercholesterolemia is an inherited disorder characterized by impaired clearance of low-density lipoprotein (LDL) cholesterol from the bloodstream, resulting in elevated LDL levels and an increased risk of atherosclerosis and cardiovascular disease. Early identification and aggressive management of hyperlipidemia are essential in individuals with familial hypercholesterolemia to reduce the risk of cardiovascular events.

Question: 11

A patient presents with sudden-onset severe chest pain, dyspnea, and hypotension. Diagnosis is:

- A. Acute arterial occlusion
- B. Acute venous thrombosis
- C. Aortic aneurysm
- D. Aortic dissection

Answer: D

Explanation: The clinical presentation of sudden-onset severe chest pain, dyspnea, and hypotension is highly suggestive of aortic dissection. Aortic dissection occurs when there is a tear in the inner lining of the aorta, leading to the formation of a false lumen and the potential for life-threatening complications. It is a medical emergency that requires immediate intervention to prevent further dissection, rupture, or organ ischemia.

Question: 12

A patient presents with severe headache, blurred vision, and epistaxis. Blood pressure measurement reveals a reading of 200/120 mm Hg. The diagnosis is:

- A. Hypertensive urgency
- B. Hypertensive emergency
- C. Essential hypertension
- D. Hypertensive crisis

Answer: B

Explanation: The clinical presentation of severe headache, blurred vision, epistaxis, and severely elevated blood pressure (200/120 mm Hg) is indicative of a hypertensive emergency. A hypertensive emergency is defined as severely elevated blood pressure associated with end-organ damage. It requires immediate blood pressure reduction with intravenous antihypertensive medications to prevent further complications, such as stroke, myocardial

infarction, or renal failure.

Question: 13

A patient with heart failure presents with worsening dyspnea, orthopnea, and bilateral lower extremity edema. The nurse auscultates crackles in the lung bases and an S3 gallop rhythm. These findings are consistent with:

- A. Acute pulmonary embolism.
- B. Acute exacerbation of chronic obstructive pulmonary disease (COPD).
- C. Right-sided heart failure.
- D. Left-sided heart failure.

Answer: D

Explanation: The patient's presentation with worsening dyspnea, orthopnea, bilateral lower extremity edema, crackles in the lung bases, and an S3 gallop rhythm is consistent with left-sided heart failure. Left-sided heart failure occurs when the left ventricle fails to effectively pump blood forward, leading to fluid accumulation in the lungs (pulmonary congestion). This results in symptoms such as dyspnea, orthopnea, and crackles on auscultation. Right-sided heart failure (option D) typically presents with peripheral edema, hepatomegaly, and jugular venous distention.

Question: 14

A patient presents with sudden-onset severe chest pain that radiates to the back. Blood pressure measurements in both arms reveal a significant difference. These findings are highly suggestive of:

- A. Acute myocardial infarction (MI).
- B. Aortic dissection.

- C. Pulmonary embolism.
- D. Pericarditis.

Answer: B

Explanation: The patient's presentation with sudden-onset severe chest pain that radiates to the back and a significant difference in blood pressure measurements between both arms is highly suggestive of aortic dissection. Aortic dissection is a life-threatening condition characterized by a tear in the inner layer of the aorta, leading to the formation of a false lumen and potential rupture of the aortic wall. The chest pain associated with aortic dissection is often described as tearing or ripping and may radiate to the back. Acute myocardial infarction (option A) typically presents with chest pain and ECG changes indicative of myocardial ischemia. Pulmonary embolism (option C) presents with sudden-onset dyspnea, pleuritic chest pain, and signs of hemodynamic instability. Pericarditis (option D) is characterized by sharp, pleuritic chest pain that is typically relieved by sitting forward and may be associated with a pericardial friction rub on auscultation.

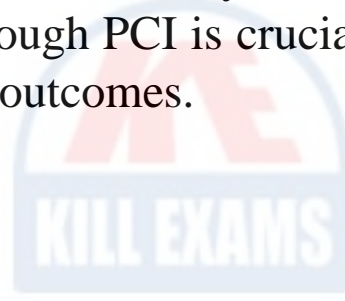
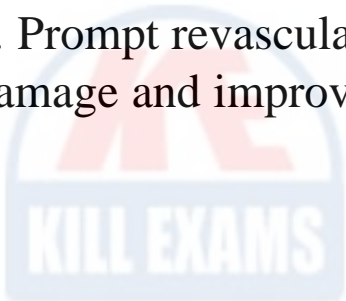
Question: 15

A patient presents with chest pain and electrocardiogram (ECG) findings consistent with ST-segment elevation myocardial infarction (STEMI). Which of the following interventions should be prioritized?

- A. Administration of fibrinolytic therapy.
- B. Initiation of antiplatelet therapy with aspirin and clopidogrel.
- C. Immediate coronary angiography and percutaneous coronary intervention (PCI).
- D. Administration of oxygen therapy.

Answer: C

Explanation: In patients with ST-segment elevation myocardial infarction (STEMI), the priority intervention is immediate coronary angiography and percutaneous coronary intervention (PCI). PCI involves the use of a catheter to open the blocked coronary artery and restore blood flow to the heart. This intervention is considered the gold standard treatment for STEMI and has shown superior outcomes compared to fibrinolytic therapy (option A). While antiplatelet therapy (option C) and oxygen therapy (option D) are important components of the overall management of STEMI, they are not the prioritized interventions. Prompt revascularization through PCI is crucial in minimizing myocardial damage and improving patient outcomes.



SAMPLE QUESTIONS



*These questions are for demo purpose only. **Full version is up to date. The questions will improve your knowledge about the exam and help you pass the exam at very first attempt.***

Killexams.com is an online platform that offers a wide range of services related to certification exam preparation. The platform provides actual questions, exam dumps, and practice tests to help individuals prepare for various certification exams with confidence. Here are some key features and services offered by Killexams.com:



Actual Exam Questions: *Killexams.com provides actual exam questions that are experienced in test centers. These questions are updated regularly to ensure they are up-to-date and relevant to the latest exam syllabus. By studying these actual questions, candidates can familiarize themselves with the content and format of the real exam.*

Exam Dumps: *Killexams.com offers exam dumps in PDF format. These dumps contain a comprehensive collection of questions and answers that cover the exam topics. By using these dumps, candidates can enhance their knowledge and improve their chances of success in the certification exam.*

Practice Tests: *Killexams.com provides practice tests through their desktop VCE exam simulator and online test engine. These practice tests simulate the real exam environment and help candidates assess their readiness for the actual exam. The practice tests cover a wide range of questions and enable candidates to identify their strengths and weaknesses.*

Guaranteed Success: *Killexams.com offers a success guarantee with their exam dumps. They claim that by using their materials, candidates will pass their exams on the first attempt or they will refund the purchase price. This guarantee provides assurance and confidence to individuals preparing for certification exams.*

Updated Content: *Killexams.com regularly updates its question bank and exam dumps to ensure that they are current and reflect the latest changes in the exam syllabus. This helps candidates stay up-to-date with the exam content and increases their chances of success.*

Technical Support: *Killexams.com provides free 24x7 technical support to assist candidates with any queries or issues they may encounter while using their services. Their certified experts are available to provide guidance and help candidates throughout their exam preparation journey.*

For More exams visit <https://killexams.com/vendors-exam-list>
Kill your exam at First Attempt....Guaranteed!